

DIAGNOSE THIS

An 88 Year-Old Woman with Syncope

Peter Reardon BScH¹, Ismail Cajee MB ChB²

¹Class of 2014, Faculty of Medicine, Dalhousie University

²Department of Emergency Medicine, Dalhousie University

An 88 year-old woman presents to the emergency department with an episode of syncope. She was witnessed to, “suddenly slump forward in her chair for approximately 30 seconds.” She had bilateral hip replacements in 2004. She is on no other medications. Past medical history is otherwise unremarkable.

On examination she is tachycardic and tachypneic. Physical examination is otherwise unremarkable. A plain film chest x-ray is performed.

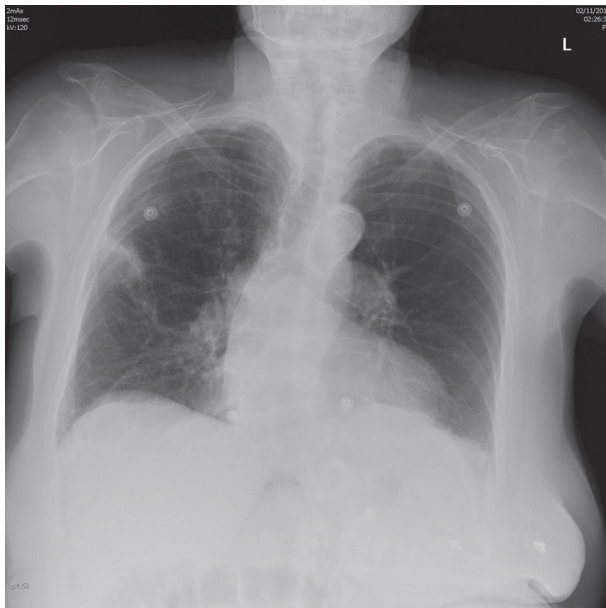


Figure 1. Posterior-anterior chest radiograph

What is the diagnosis?

- A. Pneumonia
- B. Congestive heart failure
- C. Myocardial infarction
- D. Pulmonary embolus
- E. Sarcoidosis

MAKE THE RIGHT CALL

For the best selection of reference books and materials,
call the Health Sciences Bookstore.




From school to practice, we're always on call for you.
Come by or visit our blog today.

Visit Us at:
Dentistry Building
Health Sciences Bookstore
5981 University Avenue
Tel: 902.494.3020

VISIT OUR BLOG



 **DALHOUSIE
UNIVERSITY**
BOOKSTORES
www.bookstore.dal.ca

The correct answer is:

- A. Pneumonia
- B. Congestive heart failure
- C. Myocardial infarction
- D. Pulmonary embolus
- E. Sarcoidosis

Overview

Pulmonary embolus (PE) is the third most common acute cardiovascular disease after myocardial infarction and stroke.¹ It carries significant potential for morbidity and mortality with a three-month all-cause death rate of 17.4%.² Accurate diagnosis of PE with risk stratification and early intervention can reduce mortality.¹

Radiographic Findings

The chest radiograph is fundamental to the initial diagnostic evaluation of pulmonary embolus with the benefit of being noninvasive and exposing the patient to relatively little radiation.³ The radiographic findings of PE cases are widely variable with up to 24% of the results being normal.² Of the abnormal, the most common findings are nonspecific such as cardiomegaly, atelectasis, pleural effusion, elevated hemidiaphragm, and pulmonary artery enlargement (Table 1).²⁻⁴

This patient's posterior-anterior chest radiograph demonstrates a pleural based, wedge-shaped opacity, in the mid-right lung, otherwise known as a Hampton's hump (Fig. 2). This sign, although infrequent (5% of cases),¹⁻³ is classically representative of pulmonary embolus.¹ The opacification is caused by alveolar wall necrosis accompanying alveolar hemorrhage, due to

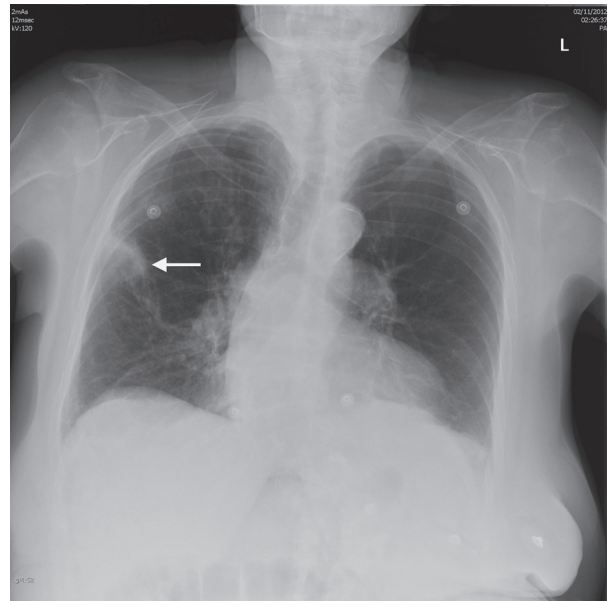


Figure 2. Posterior-anterior chest radiograph. Hampton's hump (arrow) is a classic sign of PE.

pulmonary infarction.⁵ This patient's chest radiograph also demonstrates bibasilar atelectasis.

Although not displayed in this case, another classic sign of PE is the Westermark sign.¹ It describes an area of decreased vascularization in the periphery of the lung by means of mechanical obstruction or reflex vasoconstriction in PE.⁵ The regional oligemia is recognized on x-ray as an area of radiolucency. It is found in 8% of cases.¹⁻³

Clinical Features

Clinical manifestation of pulmonary embolus is quite variable. The most common symptoms are dyspnea and pleuritic chest pain, however patients can also present with other symptoms such as cough, syncope and hemoptysis.^{6,7} Common signs include tachypnea, tachycardia, and signs of deep venous thrombosis (eg calf swelling or pain).^{6,7} A large prospective cohort study found that 92% of patients with PE presented with either dyspnea, tachypnea, or pleuritic pain.⁶ Many different clinical decision rules incorporate these signs and symptoms to allow for a probability assessment of PE, and to assist in selection of further diagnostic modalities.

Management

Treatment decisions in PE are heavily weighted on risk stratification of the patient. The recommended initial treatment for most PE patients is anticoagulation with low molecular weight heparin (LMWH), with the initiation of a vitamin K antagonist (Warfarin).⁷ In rare occurrences, certain high risk patients may undergo

Table 1. Common chest radiographic abnormalities associated with acute pulmonary embolism.²

Abnormalities	%
Cardiac enlargement	27
Pleural effusion	23
Elevated hemidiaphragm	20
Pulmonary artery enlargement	19
Atelectasis	18
Infiltrate	17
Pulmonary congestion	14

thrombolysis, surgical embolectomy, or percutaneous embolectomy.

LMWH anticoagulation may be discontinued as the patient's INR reaches the target level of 2 - 3 for at least 2 consecutive days.⁷ Patients will remain anticoagulated on Warfarin for 3 - 6 months with treatment being extended in some cases of unprovoked PE.⁷ In patients with a second episode of unprovoked PE, long term treatment with anticoagulation is recommended.⁷

Case Conclusion

Diagnosis of pulmonary embolus was confirmed via CT scan with PE protocol. She was given low molecular weight heparin, Warfarin, and admitted to the hematology unit for monitoring.

References

1. Burns SK, & Haramati LB. Diagnostic imaging and risk stratification of patients with acute pulmonary embolism. *Cardiol Rev* 2012;20:15-24.
2. Elliott CG, Goldhaber SZ, Visani L, & DeRosa M. Chest radiographs in acute pulmonary embolism. results from the international cooperative pulmonary embolism registry. *Chest* 2000;118:33-38.
3. Zubairi AB, Husain SJ, Irfan M, Fatima K, Zubairi MA, & Islam M. Chest radiographs in acute pulmonary embolism. *J Ayub Med Coll Abbottabad* 2007;19:29-31
4. Worsley DE, Alavi A, Aronchick JM, Chen JT, Greenspan RH, & Ravin CE. Chest radiographic findings in patients with acute pulmonary embolism: observations from the PIOPED study. *Radiology* 1993;189:133-136.
5. Algin O, Gokalp G, & Topal U. Signs in chest imaging. *Diagn Interv Radiol* 2011; 17:18-29.
6. Stein PD, Beemath A, Matta F, Weg JG, Yusen RD, Hales CA, ... Woodard PK. Clinical characteristics of patients with acute pulmonary embolism: Data from PIOPED II. *Am J Med* 2007;120:871-879.
7. Torbicki A, Perrier A, Konstantinides S, Agnelli G, Galie N, Pruszczyk P, ... ESC Committee for Practice Guidelines (CPG). Guidelines on the diagnosis and management of acute pulmonary embolism: The task force for the diagnosis and management of acute pulmonary embolism of the european society of cardiology (ESC). *Eur Heart J* 2008;29:2276-2315.
8. Erdur B, Karabulut N, Turkcuer I, & Ergin A. Diagnostic work-up of patients with suspected pulmonary embolism: A survey of strategies used by emergency physicians. *Diagn Interv Radiol* 2009;15:166-171.