

Restorative Proctocolectomy

Martin Dzierzanowski¹, BSc, MD '00, and Bernard P. McIntyre², MD, FRCS(C), FACS

¹ Faculty of Medicine, Dalhousie University, Halifax, Nova Scotia

² Department of Surgery, QE II Health Sciences Centre, Halifax, Nova Scotia

The purpose of this study was to evaluate restorative proctocolectomy (RPC) as a treatment for ulcerative colitis (UC) and familial adenomatous polyposis (FAP). RPC is currently the standard treatment for patients undergoing surgery for these conditions. The evaluation is based upon results of procedures performed on 52 patients by a single physician in a tertiary care centre. The study looked at 28 females and 24 males ranging in age from 17 to 62. The median patient age was 30. Fifty patients were diagnosed with UC and 2 with FAP. There was a 15% incidence of pelvic sepsis, a 21% incidence of small bowel obstruction, and a 17% incidence of pouchitis. The procedure failed in only 2 patients (4%), who ultimately required a permanent ileostomy. There were also good clinical results regarding newly constructed neorectal reservoir function. These results suggest that RPC is a viable option for the treatment of UC and FAP.

INTRODUCTION

Ulcerative colitis (UC) is an inflammatory disease of poorly understood etiology affecting a significant portion of the population. Its incidence is 4-6 per 100,000 (1-3). Symptoms include bloody, mucoid diarrhea and severe abdominal cramping. Forty percent of patients will develop severe symptoms, which may carry grave implications of fluid and electrolyte loss and even toxicity. The most serious long-term complication is cancer (4). Cancer is also a prominent feature of untreated familial adenomatous polyposis (FAP) (5). FAP is a genetic disorder that results in the formation of an extremely large number of adenomas covering the mucosa of the large bowel. Since the risk of developing malignancy increases proportionately with the number of polyps present, FAP poses a serious threat of developing carcinoma (6,7). Taking this into consideration, a notable portion of UC patients and all FAP patients require total abdominal colectomy as a prophylactic treatment.

Since the beginning of this century, there has been an increasing interest in new

operative techniques to treat patients with UC and FAP. Attempts to preserve anal sphincter function following proctocolectomy were made as early as 1940 (8-11). Early procedures consisted of straight ileoanal anastomosis, but had very little success. Further attempts were postponed and proctocolectomy with an end ileostomy became the standard operation until the 1970s, when some successful straight ileoanal anastomosis surgeries were performed, and the first ileal pouch anal anastomosis (IPAA) was introduced (12,13). Restorative proctocolectomy (RPC) has since gained popularity and is now the procedure of choice for patients with UC and FAP. This procedure presented the first good alternative for proctocolectomy with permanent ileostomy. Permanent ileostomy was often difficult to accept, especially for young patients, who commonly elected to wait until their condition further deteriorated (14).

Presently, RPC is performed with a number of variations, all of which yield good results. Essentially, surgery consists of total colectomy followed by creation of the neorectal reservoir. Many different reservoir configurations are possible, including W, S, and J pouches. There is debate about which shape produces the best results (15). The procedure can be done with mucosectomy, especially if the anastomosis is handsewn, or without mucosectomy, if the IPAA is double-sta-

Address correspondence to:

Martin Dzierzanowski
Box 22, Sir Charles Tupper Medical Building, Dalhousie University,
Halifax, Nova Scotia B3H 4H7

pled. The benefits and risks of performing a mucosal resection have not yet been clearly established (15). Finally, many surgeons routinely opt to establish a temporary loop ileostomy. Some studies show that a temporary diversion can be safely omitted with some benefit for selected patients (16, 17).

The purpose of this study is to review the outcome of RPC as performed in 52 patients by a single surgeon in a tertiary care centre.

PATIENTS AND METHODS

Patients

Between July 1993 and February 1997 (43 months), 52 patients at the QE II Health Sciences Centre underwent the RPC procedure. Fifty patients (96%) were diagnosed with UC and 2 (4%) with FAP. Patients ranged from 17 to 62 years of age with a median age of 30 years. The group of patients consisted of 28 females and 24 males. In 35 cases (67%) the RPC was performed as a single stage procedure with no previous colectomy. Seventeen patients (33%) had an abdominal colectomy prior to the IPAA procedure.

Operative Techniques

All patients underwent mechanical bowel preparation prior to the procedure. Patients were placed in the lithotomy position. Total abdominal colectomy (if not previously done) was performed with the proctectomy at the level of the anorectal ring. The ileum was divided at the ileocecal junction or the previous stoma was freed from the abdominal wall, using caution to preserve maximum bowel length. A complete mobilisation of the root of the small bowel was performed. A J-pouch was constructed using 2 firings of a 75mm stapler-cutter, which was inserted through the enterotomies at the mid-portion of the J. In 6 patients (11%), a mucosectomy was performed and a handsewn IPAA was created at the dentate line using absorbable sutures. In the remaining patients (89%), an IPAA was performed using a double staple technique. Both doughnuts were inspected for integrity. Anastomosis was checked by air insufflation using a rigid sigmoidoscope. The decision to omit the temporary loop ileostomy was made at the end of each procedure. The two main criteria for the omission were a lack of tension on the anastomosis and no use of steroids prior to the procedure. In 41 patients (79%), a loop ileostomy was used to defunction the newly constructed neorectal reservoir.

Post-Operative Management

The first follow-up visit was scheduled one month following the IPAA if the procedure was performed without a diverting stoma. Where a diverting stoma was used, the first follow-up visit was scheduled after the ileostomy closure. Ileostomy closures were performed within 6-22 weeks following the IPAA with a median of 8 weeks.

Follow-up for this study ranged from 1 to 36 months with a median of 6 months duration. During each follow-up visit, bowel function and the patient's quality of life were as-

essed using a standard questionnaire. Noted were: the number of bowel movements within a 24 hour period, the time from the initial urge until bowel movement, and the fecal continence. Fecal continence was graded as full, spotting (i.e., staining of clothing by liquid stool or mucus), or gross fecal incontinence. Finally, any incidence of pouchitis, an inflammatory condition of the neorectal reservoir, was noted.

RESULTS

Complications

Complications encountered during the study and their frequency of occurrence are recorded in **Table 1**. There were no mortalities in this study group. Incidence of pelvic sepsis, small bowel obstruction, pouchitis, anal stricture and anovaginal fistula were recorded. Two cases (4%) failed.

Pelvic sepsis was observed in eight patients (15%). In three of those patients, infections were successfully resolved using antibiotics. In two cases, abscesses were drained percutaneously. After draining, one patient (who originally did not have a diverting ileostomy) developed a fistula and had to be defunctioned. He was still waiting for his ileostomy closure at the completion of this study. In another case, pelvic sepsis developed after the ileostomy closure, followed by a small bowel obstruction. This patient also required a diverting stoma, which was closed ten months later. In the remaining two cases, an FAP patient (with juvenile polyposis) and a UC patient, both originally without a diverting stoma, were eventually defunctioned. They were awaiting their ileostomy closures at the conclusion of this study.

Of all complications, small bowel obstruction had the highest incidence with eleven cases (21%). Most cases did not require intervention; however, one patient from this group required a post-operative laparotomy.

Another common complication was pouchitis, involving 9 patients (17%). In all cases, treatment with metronidazole was successful. There was recurrent pouchitis in five cases.

Two patients (4%) developed anal stenosis, which required dilatation. In one case treatment was successful. Poor function persisted in the second patient, who eventually required defunctioning. This case was considered a failure.

A second failure occurred in a patient who was diagnosed with Crohn's disease (CD) post-operatively. The patient was found to have perianal disease and developed an anovaginal fistula. Her pouch was excised and a permanent ileostomy was created.

Function

Bowel function was assessed according to the number of bowel movements per 24 hour period, continence (both at night and during the day), and the ability to defer defecation. Number of bowel movements at any given time during the follow-up ranged from 2 to 15 per 24 hour period with a median of 6. **Figure 1** shows the median number of bowel movements for each of the follow-up periods. Patients' ability to defer defecation ranged from 15 minutes to more than 3 hours

Table 1. Incidence of postoperative complications following RPC

Complication	Incidence (percentage incidence)*
None	30 (58%)
Death	0 (0%)
Pelvic sepsis	8 (15%)
Small bowel obstruction	11 (21%)
Pouchitis	9 (17%)
Anal stricture	2 (4%)
Anovaginal fistula	1 (2%)
Failure - pouch excision or defunction	2 (4%)

*Total exceeds 100% since some patients experienced more than one complication.

with a median of 2 hours. Forty-eight patients (92%) had perfect continence during the day, and 44 (85%) also had excellent control at night. Three patients (6%) complained of occasional staining during the day; all were in the mucosectomy group. At night, 7 patients (13%) experienced problems with occasional spotting. Only 1 patient (2%) with anal stenosis complained of gross fecal incontinence both during the day and at night and, as already stated, this procedure was considered a failure.

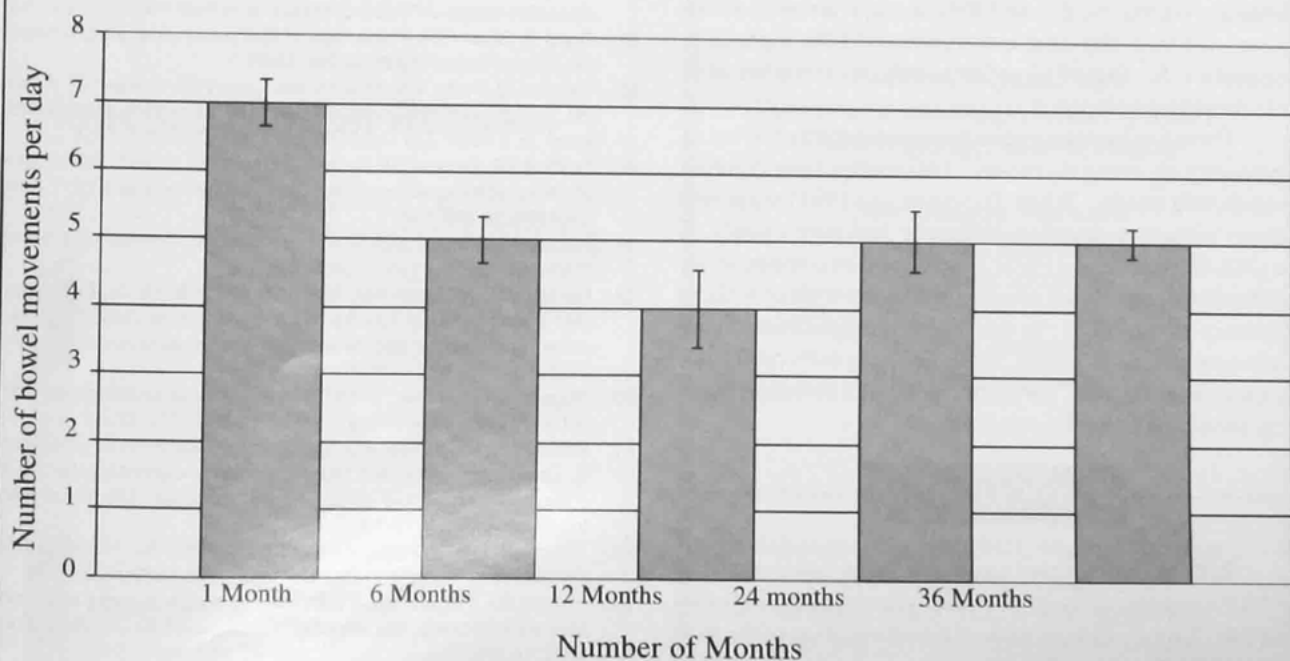
DISCUSSION

Until recently, standard therapy for FAP and severe UC involved total proctocolectomy with a permanent ileostomy. Although necessary, this procedure had a poor acceptance among both patients and physicians, and it raised significant psychosocial issues. As well, nearly 50% of patients were reported to have chronic problems related to the application of the permanent stoma (18).

Although attempts to spare the anal sphincter were undertaken in the first half of the twentieth century, it was not until the 1970s when IPAA was developed (8-13). Creation of a neorectal reservoir proximal to the ileoanal anastomosis was the most important step. This procedure quickly gained wide acceptance. This was mostly due to the fact that by providing a neorectal reservoir and preserving the sphincter, adequate continence and acceptable stool frequency were preserved (19). Today, RPC is the procedure of choice for both UC and FAP patients.

Even though there are many possibilities with respect to the anatomic make-up of the neorectal reservoir, in this study a J-pouch was constructed in all cases. Studies show that the volume of the pouch is inversely proportional to the post-operative stool frequency and that the capacity of the J-pouch increases 300-400% during the first year following an IPAA (19). It is also important to note that the J-pouch requires a significantly smaller portion of ileum than W or S construction. This is significant in the case of severe complications, where excision of the pouch is required, because more

Figure 1 Median bowel movement frequency per each follow up period. Standard Error indicated by error bars.



ileum can be preserved.

This study looked at the outcome of 52 procedures that were performed by a single surgeon in a tertiary care centre. Both the complications and functional results of this study were very encouraging, especially when compared with some recent large study groups (18). There were no deaths in this study, which is comparable to the reported 0.5% mortality previously cited. Overall, 21% of the patients developed small bowel obstruction, but the percentage of patients requiring surgical intervention was small. The 15% incidence of pelvic sepsis is comparable to other studies (20,21). The 4% failure rate also compares well to other study groups.

Post-operative diagnosis of CD in one of the patients (2%) from this study group is a well-documented complication. In 1993, Martin stated that currently available diagnostic methods occasionally cannot differentiate between Crohn's colitis and UC (14). He also reported a 12% incidence of misdiagnosis.

The most prevalent long-term complication observed during this and other studies is pouchitis. Pouchitis is a non-specific inflammation of the neorectal reservoir (22). Its symptoms comprise abdominal cramping, watery (sometimes bloody) diarrhea, urgency, fecal incontinence, malaise, and fever (23). The etiology is poorly understood; however, some explanations have been proposed. They include categories of conditions such as fecal stasis, recurrent UC, CD, and mucosal ischemia of the pouch (24). There is still some uncertainty regarding the prevalence of pouchitis in patients who have undergone IPAA. Studies report a prevalence ranging from 7% (25) to 44% (26). During this study, the prevalence of pouchitis was 17%.

The functional results of this study were extremely positive. The median frequency of 6 bowel movements was acceptable for the majority of patients. Ninety-two percent continence during the day and 85% at night are well above the reported 90% day-time continence and 60% night-time continence (18). Out of 52 patients, only one complained of gross fecal incontinence.

There has been some controversy regarding the use of a temporary diverting ileostomy. Two studies have reported contradicting results. While Tjandra *et al.* (1993) suggested patients without a diverting ileostomy had poor quality of life (16), Gorfine *et al.* (1995) concluded that complications and functional results are similar for patients with or without temporary stomas (17). In this study, no significant differences were noted. However, as suggested in both cited studies, candidates for RPC performed without a diverting ileostomy should be carefully screened.

CONCLUSION

RPC as the standard treatment for patients with UC and FAP has proven to be highly successful in increasing quality of life. Especially important is the elimination of the psychosocial implications of having a permanent end ileostomy. This study conformed very well to the standards set by the pioneers of this procedure. It yielded good results both in

incidence of complications and failures, as well as in functional results.

REFERENCES

1. Robbins SL, editor. Pathologic basis of disease. 5th ed. Philadelphia: W.B. Saunders;1994.
2. Tierney LM, McPhee SJ, Papadakis MA, editors. Current Medical Diagnosis & Treatment. 37th ed. Stamford (CT): Appelton & Lange;1998.
3. Garland CF, Lilienfeld AM, Mendeloff AI, Markowitz JA, Terrell KB, Garland FC. Incidence rates of ulcerative colitis and Crohn's disease in 15 areas of the US. *Gastroenterology* 1981;81:1115-1124.
4. Nugent FW, Haggitt RC, Gilpin PA. Cancer surveillance in ulcerative colitis. *Gastroenterology* 1991;100:1241-1248.
5. Lynch HT, Watson P, Smyrk TC, Lanspa SJ, Boman BM, Boland CR, *et al.* Colon cancer genetics. *Cancer* 1992;70(Suppl.):1300-1312.
6. Powell SM, Petersen GM, Krush AJ, Booker S, Jen J, Giardiello FM, *et al.* Molecular diagnosis of familial adenomatous polyposis. *N Engl J Med* 1993;329:1982-1987.
7. Morson BC. The polyp-cancer sequence in the large bowel. *Proc R Soc Med* 1974;67:451-457.
8. Ravitch MM, Sabiston DC. Anal ileostomy with preservation of the sphincter. *Surg Gynecol Obstet* 1947;84:1095-1099.
9. Ravitch MM. Anal ileostomy with sphincter preservation in patients requiring total colectomy for benign conditions. *Surgery* 1948;24:170-187.
10. Wangenstein OH, Toon RW. Primary resection of colon and rectum with particular referral to cancer and ulcerative colitis. *Am J Surg* 1948;75:384-404.
11. Devine J, Webb R. Resection of rectal mucosa, colectomy and anal ileostomy with normal continence. *Surg Gynecol Obstet* 1951;92:437-442.
12. Martin LW, LeCoultrre C, Schubert WK. Total colectomy and mucosal proctectomy with preservation of continence in ulcerative colitis. *Ann Surg* 1977;186:477-479.
13. Parks AG, Nicholls RJ. Proctocolectomy without ileostomy for ulcerative colitis. *BMJ* 1978;2:85-88.
14. Martin LW. Current surgical management of patients with chronic ulcerative colitis. *J Pediatr Gastroenterol Nutr* 1993;17:121-131.
15. Goes R, Beart RW. Physiology of ileal pouch anal anastomosis. *Dis Colon Rectum* 1995;38:996-1005.
16. Tjandra JJ, Fazio VW, Milsom JW, Lavery IC, Oakley JR, Fabre JM. Omission of temporary diversion in restorative proctocolectomy - is it safe? *Dis Colon Rectum* 1993;36:1007-1014.
17. Gorfine SR, Geleert IM, Bauer JJ, Harris MT, Kreef I. Restorative proctocolectomy without diverting ileostomy. *Dis Colon Rectum* 1995;38:188-194.
18. Becker JM. Ileal pouch-anal anastomosis: Current status and controversies. *Surgery* 1993;6:599-602.
19. Becker JM, McGrath KM, Meagher MP, Parodi JE, Dunnegan DA, Soper NJ. Late functional adaptation after colectomy, mucosal proctectomy, and ileal pouch-anal anastomosis. *Surgery* 1991;110:718-725.
20. Sugerman HJ, Newsome HH. Stapled ileoanal anastomosis without a temporary ileostomy. *Am J Surg* 1994;167:58-64.
21. Williamson ME, Lewis WG, Sagar PM, Holdsworth PJ, Johnston D. One stage restorative proctocolectomy without temporary ileostomy for ulcerative colitis: a note of caution. *Dis Colon Rectum* 1997;40(9):1019-1022.
22. Shepherd NA, Hulten L, Tytgat GN, Nicholls RJ, Nasmyth DG, Hill MJ, *et al.* Pouchitis. *Int J Colorectal Dis* 1989;4:205-229.
23. Fozard BJ, Pemberton JH. Results of pouch surgery after ileoanal anastomosis: the implications of pouchitis. *World J Surg* 1992;16:880-884.
24. Sandborn WJ. Pouchitis following ileal pouch-anal anastomosis: definition, pathogenesis, and treatment. *Gastroenterology* 1994;107:1856-860.

25. Dozois RR, Goldberg SM, Rothenberger DA, Utsunomiya J, Nicholls RJ, Cohen Z, et al. Restorative proctocolectomy with ileal reservoir. *Int J Colorectal Dis* 1986;1:2-19.
26. Fonkelsrud EW. Endorectal ileoanal anastomosis with isoperistaltic ileal reservoir after colectomy and mucosal proctectomy. *Ann Surg* 1984;199:151-157.

AUTHOR BIOGRAPHY

Martin Dzierzanowski is a third year medical student at Dalhousie University. He completed his undergraduate degree at Saint Mary's University in Halifax. His background is in biology and computer science. Prior to attending St. Mary's, he studied at the Academy of Physical Education in Warsaw, Poland. Martin has a particular interest in surgery and is planning to specialize in a surgical field.

Grenfell Regional Health Services

If you are a General Practitioner or Specialist who has an interest in working in a rural environment, then you may be the type of physician that Grenfell Regional Health Services is seeking to join our multidisciplinary health care team which provides integrated care for the people of Northern Newfoundland and Southern Labrador.

Salary scales for General Practitioners range from \$67,471.00 to \$99,960.00 yearly. Specialist salaries range from \$84,975.00 to \$102,506.00 yearly. Depending on location, physicians are also eligible for a non-pensionable geographic supplement of \$15,600.00 to \$31,200.00 per year and a retention incentive of \$10,000.00 to \$20,000.00 which is paid at the end of two years.

Dr. Jez Hillard

Director of Medical Services
Grenfell Regional Health Services
St. Anthony, Newfoundland
AOK 4S0
Tele: (709) 454-3333, Ext. 127
(709) 454-8596 (Home)
Fax: (709) 454-2052
E-Mail - jhillard@thezone.net

Hoechst Marion Roussel

Healthcare
to live by



Hoechst

Hoechst Marion Roussel
The Pharmaceutical Company of Hoechst

Opportunities for Specialists

Amherst, Highland View
Obstetrics/Gynaecology, Adult Psychiatry,
Otolaryngology, General Surgery

New Glasgow, Aberdeen
Orthopedics, Anaesthesia,
Diagnostic Imaging

Truro, Colchester
Adult Psychiatry, Urology

Please contact:

Shaun MacCormick MD, Medical Director
Northern Regional Health Board
44 Inglis Place, Truro, N.S. B2N 4B4
Tel 902 897-6265 Fax 902 893-0250