

The Surgical Treatment of Parkinson's Disease

K. Adam Baker, BSc(Hon), MSc '99

Department of Anatomy and Neurobiology, Dalhousie University, Halifax, Nova Scotia

Parkinson's disease (PD) is a debilitating disorder characterized by degeneration of the nigrostriatal pathway resulting in decreased caudoputaminergic dopamine (DA) levels. Nigrostriatal pathway degeneration and reduced DA stores may lead to increased rigidity, gait and speech disturbances, bradykinesia and resting tremors. Currently there is no cure for PD, but early treatment consists of Levodopa (L-dopa) therapy. With long-term L-dopa use, there is development of the 'on-off phenomenon' and dyskinesias. In the majority of PD cases, L-dopa adequately controls the motor symptoms inherent to PD, but a small percentage of the Parkinsonian population is medically-intractable to this therapy. Many clinical trials are currently being conducted world-wide to investigate the efficacy of surgery to treat this disease. These surgical therapies include ablative procedures, chronic deep brain stimulation, as well as the transplantation of dopaminergic cells. Neurosurgical treatment of PD is not a new concept, being attempted as early as the 1930's, but these procedures were plagued with many side effects that led to their abandonment. Currently, a resurgence in these techniques has evolved due to our increased understanding of basal ganglia anatomy and physiology along with recent advances in medical technology. This review will briefly discuss the benefits and short-comings of these surgical paradigms as well as the rationale behind their application.

INTRODUCTION

Parkinson's disease (PD) was first described in 1817 by the British physician, James Parkinson, as a disorder characterized by resting tremor, rigidity, slowing of movement (bradykinesia), failure to initiate movements (akinesia), flexed posture, disturbed gait and decreased coordination (1, 2). PD is more prominent in the elderly, affecting approximately 1% of the population over the age of 60 years. Decreased dopamine (DA) levels within the caudate nucleus and putamen are believed to be the contributing factor to the motor impairments observed in Parkinsonian patients. The decrease in caudoputaminergic DA levels results from the degeneration of the dopaminergic (DAergic) neurons of the substantia nigra pars compacta (SNc) that innervate the caudoputamen (3).

Over the past century, many surgical and pharmacological therapies have been de-

veloped to treat Parkinsonian motor deficits. The most dramatic alleviation of Parkinsonian motor impairments was realized during the middle of this century through administration of the dopamine precursor, levodopa (L-dopa) or Sinemet® (carbidopa/levodopa). L-dopa is decarboxylated to produce the neurotransmitter dopamine (4). At first glance, L-dopa appeared to be a 'miracle cure' for PD, but with long-term use, the efficacy of L-dopa decreases and the "on-off" phenomenon emerges (5). The "on-off" phenomenon is characterized by periods of dyskinetic movements in the "on" period followed by an unpredictable onset of akinesia (in 6).

The continued deterioration of motor function in Parkinsonian patients receiving L-dopa therapy has made it necessary to find an alternative therapy for the treatment of PD. Surgical treatment of PD has been employed for the better part of this century but with improved surgical techniques and our increased knowledge of basal ganglia anatomy and physiology, these surgical therapies are now safer and more effective. Currently, there are several surgical procedures for the treatment of PD which include either inactivation

Address correspondence to:

K. Adam Baker, Department of Anatomy and Neurobiology, Neural Transplantation Laboratory, Sir Charles Tupper Medical Building, Dalhousie University, Halifax, Nova Scotia, B3H 4H7

of a basal ganglia structure or the implantation of DAergic-rich tissue. Many clinical trials are being conducted worldwide to establish the efficacy and safety of these techniques for the treatment of PD. This paper will review some recent clinical trials using the various surgical procedures for treatment of PD and provide a rationale for these procedures with respect to basal ganglia anatomy and physiology.

BASAL GANGLIA ANATOMY AND PHYSIOLOGY

By understanding basal ganglia circuitry and physiology, the rationale for current surgical approaches to the treatment of PD becomes evident. The striatum, or caudoputamen is the main basal ganglia structure receiving topographically organized (7) motor-related inputs from the motor (8) and somatosensory cortices (9), as well as the frontal eye fields (10). The motor, premotor and somatosensory cortices project predominantly to the putamen, and the association cortices to the caudate nucleus (8). The descending corticostriatal projections are glutamatergic (11) and thus excitatory upon striatal neurons (see Figure 1). In rats, the striatum provides γ -aminobutyric acidergic (GABAergic) efferent innervation of the globus pallidus external (GPe) and internal (GPi) segments (12, 13) and the substantia nigra pars reticulata (12).

PD pathology is marked by degeneration of the nigrostriatal pathway (reviewed in 14) and thus it is first important to discuss this projection pathway from the substantia nigra pars compacta (SNc) to the striatum (Figure 1). The SNc receives excitatory innervation from the motor cortex

(15) along with inputs from the amygdala, dorsal raphe nucleus (16) and pedunculopontine tegmental nucleus (17). The excitatory nigrostriatal pathway from the SNc to the striatum depolarizes the inhibitory striatopallidal projection neurons innervating both internal and external segments (12, 13). The death of the DAergic neurons in the SNc would effectively abolish the inhibitory drive of the striatum upon the pallidum (Figure 1).

GABAergic striatopallidal fibres innervating the GPe are part of the indirect striatal motor output pathway to the cortex through the subthalamic nucleus (STN) and thalamus, whereas the direct pathway involves the direct projection of GPi upon the thalamus (8). Both pallidal projections from the GPe to the STN and GPi to the thalamus are inhibitory on the glutamatergic neurons comprising these nuclei (11, 15, 18). An interesting and important feature of the basal ganglia-motor circuit arises when considering the inhibitory pallidothalamic and pallidosubthalamic projections. GABAergic neurons projecting from the striatum to the GPi and GPe inhibit the GABAergic neurons of these structures. This process is known as disinhibition and serves to reduce the inhibition of tonically active structures (19). Thus, during resting conditions (Figure 1) the function of pallidal neurons, which may also receive innervation from an as yet unidentified structure, is to inhibit the tonically active subthalamic and thalamic neurons (8). During resting conditions (no movement), a simple explanation may be that during periods of rest, the indirect motor output pathway (GPe \rightarrow STN \rightarrow GPi \rightarrow thalamus) is primarily involved since the direct motor pathway is inactive. Without inhibition of the toni-

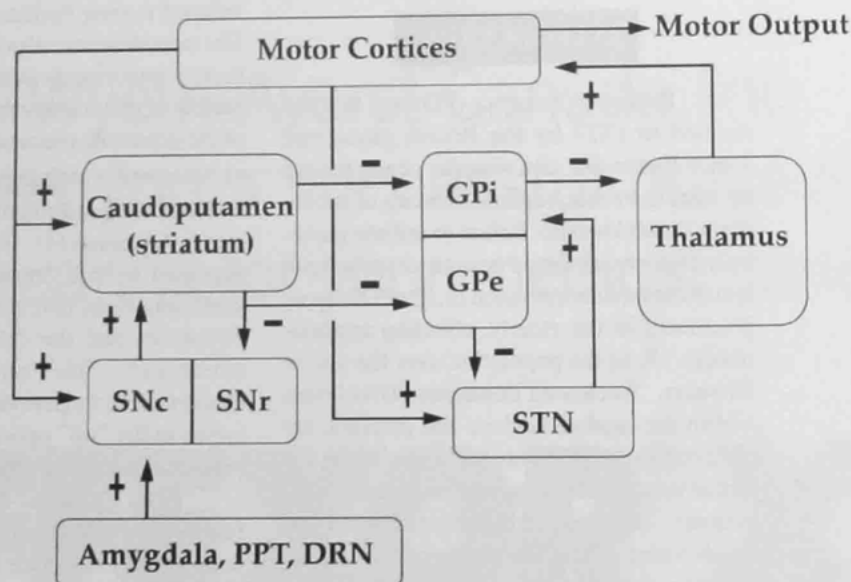


Figure 1

A simplified schematic diagram of the basal ganglia motor circuit. 'Motor output' is used to generalize all descending motor pathways. For simplicity, only pathways pertinent to this discussion are included. During rest, the indirect motor output pathway (GPe \rightarrow STN \rightarrow GPi \rightarrow thalamus) is primarily involved and the direct motor pathway (GPi \rightarrow thalamus) is inactive. During periods of activity, the direct motor output pathway is primarily involved. SNc, substantia nigra pars compacta; SNr, substantia nigra pars reticulata; GPi, internal segment of the globus pallidus; GPe, external segment of the globus pallidus; PPT, pedunculopontine tegmental nucleus; DRN, dorsal raphe nucleus; STN, subthalamic nucleus; +, excitatory pathway; and -, inhibitory pathway.

cally-active subthalamic neurons, the subthalamic nucleus is free to excite the GPi, which inhibits the thalamic neurons projecting upon the supplementary, primary and premotor cortices (20, 21).

During periods of activity (Figure 1), the direct motor output pathway (GPi → thalamus) is primarily involved. The nigrostriatal pathway receives a net excitatory input from cortical and brainstem areas, depolarizing the inhibitory striatopallidal neurons projecting to GPi and GPe. With the inhibition of GABAergic GPe neurons, the inhibitory drive upon the tonically active subthalamic neurons projecting to the GPi (22) is alleviated. These subthalamic neurons then project to the GPi, exciting the inhibitory pallidothalamic projections comprising this nucleus (20), which are inhibited by the direct pathway. This would effectively reduce the inhibitory drive of the pallidothalamic pathway and so allow the tonically-active thalamic neurons to excite motor cortical areas.

BASAL GANGLIA ANATOMY AND PHYSIOLOGY IN PD

With an understanding of the basic neuroanatomical connections of the basal ganglia motor loop, the motor impairments encountered in PD can be partially explained. With the loss of the DAergic nigrostriatal efferents, the circuit closely resembles that of the resting condition even during periods of planned motor activity. With decreased striatal innervation by the SNc, disinhibition within both the direct and indirect pathways decreases (Figure 2). Within the indi-

rect pathway, a loss of disinhibition results in a reduction of hyperpolarizing drive upon the tonic subthalamic neurons innervating GPi, by the non-tonic GABAergic GPe neurons. Increased activity of subthalamopallidal projections would increase the excitation of inhibitory GPi neurons projecting upon the thalamus. Inactivation of the direct pathway reduces the disinhibitory effects of striatopallidal projections upon the pallidothalamic pathway. Therefore, the net effect would be a hyperpolarizing drive of GPi projections upon the thalamus reducing thalamocortical excitation of cortical motor areas (Figure 2), resulting in reduced motor activity, which has been verified in PD patients (23). Although this simple explanation seems feasible, disinhibition of the subthalamic nucleus is not the only explanation for reduced cortical excitation. Recent evidence suggests that with PD there is increased excitatory drive from the motor cortex upon the STN, which may enhance the excitatory influence of the STN upon the GPi (24).

An alternative explanation for Parkinsonian tremor has been entertained that is unrelated to subthalamic activity. Subsets of thalamic (25) and GPi neurons (26) have been described which have a firing rate at tremor frequency in PD patients. The thalamic neurons lie anterior to the principal somatosensory nucleus, nucleus ventralis caudalis, in a location identified as the optimal site for placement of lesions to alleviate Parkinsonian tremor (25). Considering the poor efficacy of GPi pallidotomy in treating parkinsonian tremor (27), the pathophysiology of thalamic neurons with tremor-like frequency may be more directly involved in the production of tremor.

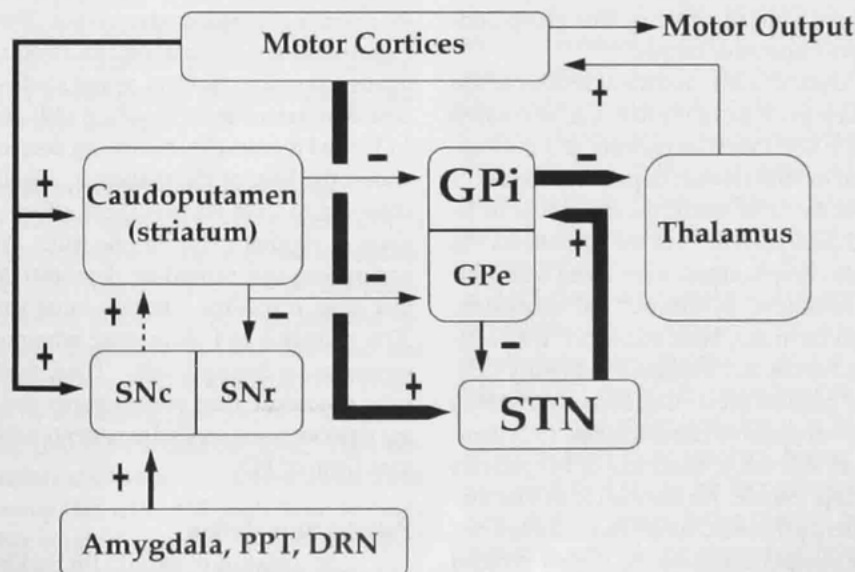


Figure 2
A simplified schematic diagram of the proposed basal ganglia motor circuitry and physiology in PD. Reduced inhibition of the tonically-active STN neurons results in increased inhibition of the thalamus via the pallidothalamic pathway. Ventroposterolateral GPi pallidotomy and GPi stimulation effectively inactivates this structure reducing the inhibitory influence upon the thalamus by GPi. Broken line, degenerating nigrostriatal pathway; thin lines, pathways with reduced activity; medium width lines, physiologically normal pathways; thick lines, over-active pathways. For more information on definitions, see description for Figure 1.

The above model implicates the primary involvement of two structures in the hypokinetic/akineti and rigidity characteristics of PD; the STN and the GPi. Two surgical procedures have been incorporated to inactivate over-active basal ganglia structures: ablation and high-frequency stimulation. Another procedure has also been developed which involves the elevation of striatal DA levels and reconstitution of basal ganglia physiology through the transplantation of DA-rich tissue sources (for a recent review, see 28).

SURGERY FOR PD - ABLATIVE PROCEDURES

Thalamotomy

Stereotactic thalamotomy was the treatment of choice up until the late 1960's for PD and largely disappeared as a therapeutic option with the introduction of L-dopa (29). Thalamotomy is an ablative procedure that involves lesioning areas of the thalamus comprised of neurons displaying tremor-like bursting activity in PD patients (25). Ablation of these neurons appears to ameliorate Parkinsonian tremor. In 1983, Tasker and colleagues reported that lesioning the ventral intermediate nucleus of the thalamus abolished tremor in 82% of a total of 75 subjects at 2 years follow-up (29). There was no observed reduction in movement or speech deficits and 7% of the patients presented with persistent complications. One year later, Matsumoto and colleagues (30) reported on the long-term follow-up (mean = 4.2 years) of 78 PD patients who underwent uni- or bilateral ventrolateral thalamotomy. In 44 of these patients, no progression of the disease was noted and in some patients there was a decrease in the L-dopa dose administered. No results were reported by this group concerning the extent of post-operative tremor.

In more recent clinical trials, unilateral lesions of the ventral intermediate nucleus (Vim) of the thalamus decreased contralateral tremor in 100% (N=8) of patients at 3 post-operative months (31) and in 86% (N=42) of patients upon a 13 year follow-up (32). In the latter study, the daily dose of L-dopa administered had decreased in 35 of the 42 patients. In this study, postoperative complications were noted which included contralateral weakness, dysarthria, and confusion. Bilateral thalamotomies have also been associated with cognitive and speech disturbances and increased morbidity (33). The high percentage of patients presenting immediate (58%) and persistent (23%) postoperative complications (32) demonstrates the need for an alternative treatment of PD patients with medically intractable tremor. An alternative to Vim thalamotomy is high-frequency thalamic stimulation (see below), in which postoperative complications can be largely avoided by repositioning the electrode if side effects are observed.

Pallidotomy

In Sweden during the 1950's, Lars Leksell improved upon an experimental surgical technique used in the 1930's for the treatment of PD, known as pallidotomy (reviewed in 34). This surgical procedure involves inactivation of the GP, which exhibits abnormal physiological activity in the Parkinsonian brain (35). Early lesions of the posteroventral GPi by

Leksell greatly reduced resting tremor, rigidity and bradykinesia in PD patients (reviewed in 34). Early pallidotomies by Leksell and others were met with a variety of side effects, including homonymous hemianopsia, transient dysphasia and transitory hemiparesis. Despite the dramatic alleviation of motor abnormalities, the side effects led to the abandonment of this technique as a therapeutic option for the treatment of Parkinsonism.

With the advent of more advanced technology (ie., imaging techniques) and improved surgical techniques (ie., computerized tomography-guided stereotactic surgery), the possible treatment of PD by pallidotomy has resurfaced (34). Since 1985, many PD patients have received this procedure for the treatment of their Parkinsonian symptoms. Many researchers have observed a dramatic improvement in speech, rigidity, time in the 'off' state as well as the severity and frequency of L-dopa-induced dyskinesias up to 1 (34, 36-45) and 4 (46) years, postoperatively. Pallidotomy has been demonstrated to only occasionally result in a reduction of anti-Parkinsonism medications and is less effective than thalamotomy for the treatment of tremor-dominant PD (27), although Laitinen and colleagues (34) reported an almost complete abolishment of tremor in 81% of patients.

SURGERY FOR PD - HIGH FREQUENCY STIMULATION

Thalamic Stimulation

In 1987, Benabid and colleagues (47) were the first to apply high-frequency electrical stimulation of the thalamus for the treatment of PD and observed a significant decrease in the severity of postoperative tremor. The mechanism by which high-frequency stimulation inactivates a brain structure remains unknown. Several recent studies have observed a decrease in tremor at 3 (33, 48), 6 (49) and 10 months (50) and 1 (33) and 8 years (51) following deep electrode implantation within the Vim of the thalamus. Thalamic stimulation was observed to have no beneficial effect on gait (49), bradykinesia or rigidity (51). In one study (51), 31.6% of patients undergoing this procedure demonstrated minor side effects that were reversible. In this same study (51), there was a 30% reduction in L-dopa dose administered as compared to preoperative dosing levels. Thus, thalamic stimulation is a safer procedure than thalamotomy and is effective at reducing tremors when applied to patients exhibiting a tremor-dominant form of PD.

Pallidal Stimulation

Stimulation of the GPi for Parkinsonian symptoms has recently been incorporated as an alternative to GPi pallidotomy for the treatment of this disease. Pallidal stimulation involves high-frequency stimulation of the ventroposterolateral GPi which effectively inactivates this structure, in comparison to low-frequency stimulation which enhances the motor symptoms (52). As mentioned above, GPi pallidotomy is occasionally met with varying transient and long-term side effects due primarily to the close proximity of the optic tract to the GPi (34, 53). GPi stimulation is beneficial by being revers-

ible in that the microelectrode can easily be repositioned if incorrectly placed. This was demonstrated by Gross and colleagues (52), where a patient reported a transient flash of light when the stimulator was turned on, suggesting incorrect positioning of the electrode near the optic tract.

In the clinical studies reported thus far there has been a demonstrated reduction in akinesia, rigidity, as well as decreased gait and speech disturbances (52, 54-57) up to 3 years post-implantation. Gross and colleagues (52) reported a decrease in tremor in 4 of 5 patients up to 3 years post-implantation, whereas other groups (54-56) failed to report any changes or reduction in tremor frequency. A similar reduction in rigidity and akinesia has been reported in MPTP-treated monkeys following GPi stimulation (58). Thus, it appears that GPi stimulation is similar to posteroventral pallidotomies in that both procedures inactivate the GPi and similarly reduce akinesia, rigidity and improve gait and speech disturbances. The main difference between these two procedures is that GPi stimulation is reversible whereas pallidotomy is not.

SURGERY FOR PD - NEURAL TRANSPLANTATION

The aim of intracaudoputaminial transplantation of DA-rich tissue is to provide functional reinnervation of host caudoputamen and elevate caudoputamen DA levels re-establishing normal basal ganglia physiology. Although transplantation was experimentally evaluated in animal models of PD in the late 1970's, it was not until the mid-1980's that the first clinical trials were conducted. Early trials investigating the efficacy of transplantation in treating PD incorporated one of two tissue sources, that of adrenal medullary or fetal ventral mesencephalon (for a brief history of neural transplantation in the treatment of PD, see 59).

Autotransplantation of Adrenal Medullary Tissue

Realizing that adrenal medullary cells produce DA, it was believed by Madrazo and colleagues (60) that transplantation of this tissue derived from the same patient (autotransplantation) may circumvent possible graft rejection and reduce Parkinsonian motor disability. In 1987, Madrazo and colleagues (60) reported on their success in treating two young Parkinsonian patients by autotransplantation of DA-rich adrenal medullary tissue into the caudate nucleus. They observed an almost complete abolishment of motor impairment at 3-10 months follow-up (60, 61). Although these findings were remarkable, other surgical teams (62-64) were instead met with transient morbidity, mortality, little improvement in older patients and a gradual return of Parkinsonian symptoms. Experimental results obtained in the rat model of PD implicate poor graft survival (65) and a loss of DAergic phenotype by the grafted cells (66) as the possible mechanism for the reappearance of PD symptoms.

The failure of other research teams to repeat Madrazo's findings has led to the abandonment of adrenal medullary tissue transplantation for the treatment of PD. In the late 1970's and early 1980's much experimental evidence had been gen-

erated to suggest that transplantation of fetal ventral mesencephalic tissue (FVM) may provide a more ideal source of DAergic tissue for the treatment of PD. Many clinical trials world-wide have been conducted to evaluate the safety and efficacy of this procedure.

Transplantation of FVM Tissue

Prior to transplantation, the ventral mesencephalon is dissected out of human fetuses of a particular age and screened for viral pathogens. The tissue is first dissociated and suspended in medium prior to transplantation or transplanted directly as solid tissue. Many clinical trials have thus far been performed using FVM tissue, but it is difficult to compare results between groups due to inconsistencies in the volume of transplanted tissue, variations in graft placement, gestational age of tissue source and form of transplanted tissue (solid versus suspension). All of these factors must be addressed in order to establish the most effective procedure for transplantation (reviewed in 6, 28). The results reported below have been dealt with as a whole, but procedural differences between trials may account for differences in the results obtained.

Neural transplantation is well tolerated with only occasional, transient side-effects being observed (67-70). Recent electron microscopic analyses of the grafts in PD patients who received FVM grafts, have demonstrated that the tyrosine hydroxylase (TH)-immunoreactive cells survive for at least 18 months and reinnervate the caudoputamen in a patch-matrix fashion forming synaptic connections (71-73). At 6 months post-transplantation, a significant amelioration of bradykinesia, rigidity, percentage 'off' time, 'on-off' fluctuations, reduced severity of dyskinesias during 'on' periods and enhanced overall motor function is observed (67, 74-77). One study reported a dramatic 64% reduction in the dose of L-dopa administered (74), although other studies demonstrated little reduction in the dose given (67, 75-77). At one year postoperatively, these improvements are sustained and in the majority of cases the dose of L-dopa administered was below preoperative levels (70, 74, 78-80). In some trials, an increase in [18F]-fluorodopa uptake was observed in the caudoputamen as visualized by positron emission tomography (70, 79). These results have been reported to persist for 18 (81, 82), 36 (83, 84), 46 (79) and 60 (69) months postoperatively.

Neural transplantation is in its infancy and a number of issues need to be resolved before transplantation for the treatment of PD can be incorporated as a routine therapy. Among these issues facing clinical programs are the ethical concerns surrounding the use of fetal tissue and its relative short supply. Currently, stem cells and tissue derived from other species are being investigated as possible alternative tissue sources. A recent study has reported on the survival and axonal outgrowth from fetal pig VM grafts (85). Although fetal porcine tissue has been shown to survive for at least 7 months in the human caudoputamen, the search for other possible tissue alternatives continues.

CONCLUSIONS

Treatment of medically-intractable PD through surgical means is becoming more prominent in the clinical setting, but no one technique appears to be ideal for the treatment of all cases of PD. The ablative procedures presently employed can be replaced by the safer and reversible stimulation procedures. Our increasing understanding of basal ganglia anatomy and physiology has made it possible to predict the optimal site for placement of microelectrodes or lesions. Experimental studies are beginning to investigate the subthalamic nucleus as another possible site for inactivation in animal models of PD (86-88). In a recent clinical trial, Limousin and colleagues (89) demonstrated that the clinical benefits associated with subthalamic stimulation are the same as those of ventroposterolateral GPi stimulation, although a slightly greater benefit was observed with subthalamic stimulation. Further studies are needed to evaluate the significance of these results, since it has been noted that over-stimulation of the STN may lead to hemiballistic movements (90). Not only are advances being made in the surgical treatment of PD, but many therapeutic drugs are also being investigated in clinical trials for their ability to control Parkinsonian motor impairments. Such pharmacological treatments of PD include DA receptor agonists (91), monoamine oxidase B inhibitors (92) as well as glutamate receptor antagonists (93).

Of the surgical techniques, ventroposterolateral GPi inactivation is effective in treating bradykinesia and rigidity, whereas thalamic inactivation is more appropriate in treating tremor-dominant PD. It appears unlikely that a cure for all PD patients will involve only one type of therapy. Instead the therapy may have to be tailored to the particular symptoms exhibited by the individual patient. Transplantation of FVM tissue has been shown to reduce all Parkinsonian symptoms and may hold as a possible treatment for all types of PD and L-dopa-induced symptoms. Recent experiments incorporating the rat model of PD have demonstrated that more complete behavioural recovery is established by grafting in both caudoputamen and substantia nigra (94). It has similarly been demonstrated that graft fibre outgrowth is enhanced by pretreatment of the tissue with glial cell line-derived neurotrophic factor (95, 96). These experimental findings may prove of value in the clinical setting, but the future of transplantation may more closely depend on the discovery of an abundant, alternative tissue source. Such an alternative may be neuronal progenitors that are capable of both proliferation and differentiation in culture (for a review, see 97).

ACKNOWLEDGEMENTS

The author would like to thank Dr. Ivar Mendez, Department of Surgery (Division of Neurosurgery) and Karim Mukhida for helpful suggestions in the preparation of this manuscript.

REFERENCES

1. Tapper, VJ. Pathophysiology, assessment and treatment of Parkinson's disease. *Nurse Pract* 1997; 22: 76-95.
2. Youdim MBH & Riederer P. Understanding Parkinson's Disease. *Sci Amer* 1997; 276: 52-59.
3. Hirsch EC. Biochemistry of Parkinson's disease with special reference to the dopaminergic systems. *Mol Neurobiol* 1994; 9: 135-142.
4. Weiner N & Molinoff PB. Chapter 12. Catecholamines. In: Siegel, GW, Agranoff BS, Albers RW & Molinoff PB, editors. *Basic Neurochemistry* (5th ed.). New York: Raven Press Ltd.; 1994: pp. 261-281.
5. Marsden CD & Parkes JD. Success and problems of long-term levodopa therapy in Parkinson's disease. *Lancet* 1977; 1: 345-349.
6. Chisholm AH. Fetal tissue transplantation for the treatment of Parkinson's disease: A review of the literature. *J Neurosci Nursing* 1996; 28: 329-338.
7. Kunzle H. Bilateral projections from precentral motor cortex to the putamen and other parts of the basal ganglia. An autoradiographic study in *Macaca fascicularis*. *Brain Res* 1975; 88: 195-209.
8. DeLong MR, Alexander GE, Mitchell SJ & Richardson RT. The contribution of basal ganglia to limb control. *Prog Br Res* 1986; 64: 161-174.
9. Kunzle H. Projections from the primary somatosensory cortex to basal ganglia and thalamus in the monkey. *Exp Br Res* 1977; 30: 481-492.
10. Kunzle H & Albert K. Efferent connections of cortical, area 8 (frontal eye fields) in *Macaca fascicularis*. A reinvestigation using the autoradiographic technique. *J Comp Neurol* 1977; 173: 153-164.
11. Kaneko T & Mizuno M. Immunohistochemical study of glutamate-containing neurons in the cerebral cortex and thalamus of the rat. *J Comp Neurol* 1988; 267: 590-602.
12. Loopujit LD & Van Der Rooy D. Organization of the striatum: collateralization of its efferent axons. *Br Res* 1985; 348: 86-99.
13. Rajakumar N, Elisevich K & Flumerfelt BA. The pallidostriatal projection in the rat: a recurrent inhibitory loop? *Br Res* 1994; 651: 332-336.
14. Hirsch EC. Biochemistry of Parkinson's disease with special reference to the dopaminergic systems. *Mol Neurobiol* 1994; 9: 135-142.
15. Schmidt WJ. Balance of transmitter activities in the basal ganglia loops. *J Neural Transm* 1995; 46 (suppl.): 67-76.
16. Vertes RP. A PHA-L analysis of ascending projections of the dorsal raphe nucleus in the rat. *J Comp Neurol* 1991; 313: 643-665.
17. Clarke PBS, Hommer DW, Pert A & Skirroll LR. Innervation of substantia nigra neurons by cholinergic afferents from pedunculopontine nucleus in the rat: neuroanatomical and electrophysiological evidence. *Neurosci* 1987; 23: 1011-1019.
18. Smith Y & Parent A. Neurons of the subthalamic nucleus in primates display glutamate but not GABA immunoreactivity. *Br Res* 1988; 453: 353-356.
19. Chevalier G & Deniau JM. Disinhibition as a basic process in the expression of striatal functions. *Trends Neurosci* 1990; 13: 277-280.
20. Nambu A, Yoshida S & Jinnai K. Projection to motor cortex of thalamic neurons with pallidal input in the monkey. *Exp Br Res* 1988; 71: 658-662.
21. Schell GR & Strick PL. The origin of thalamic inputs to the arcuate premotor and supplementary motor areas. *J Neurosci* 1984; 4: 539-560.
22. Albin RL, Young AB & Penney JB. The functional anatomy of basal ganglia disorders. *Trends Neurosci* 1989; 12: 366-375.
23. Rascol O, Sabatini U & Choller F. Supplementary and primary sensory motor area activity in Parkinson's disease. Regional cerebral blood flow changes during finger movements. *Arch Neurol* 1992; 49: 144-148.
24. Levy R, Hazrati LN, Herrero MT, et al. Re-evaluation of the func-

- tional anatomy of the basal ganglia in normal and Parkinsonian states. *Neurosci* 1997; 76: 335-343.
25. Lenz FA, Normand SL, Kwan HC, et al. Statistical prediction of the optimal site for thalamotomy in Parkinsonian tremor. *Mov Disord* 1995; 10: 318-328.
 26. Hutchison WD, Lozano AM, Tasker RR, et al. Identification and characterization of neurons with tremor-frequency activity in human globus pallidus. *Exp Brain Res* 1997; 113: 557-563.
 27. Tasker RR, Lang AE & Lozano AM. Pallidal and thalamic surgery for Parkinson's disease. *Exp Neurol* 1997; 144: 35-40.
 28. Mehta V, Spears J & Mendez I. Neural transplantation in Parkinson's disease. *Can J Neurol Sci* 1997; 24: 292-301.
 29. Tasker RR, Siqueira J, Hawrylyshyn P & Organ LW. What happened to Vim thalamotomy for Parkinson's disease? *Appl Neurophysiol* 1983; 46: 68-83.
 30. Matsumoto K, Shichijo F & Fukami T. Long-term follow-up review of cases of Parkinson's disease after unilateral or bilateral thalamotomy. *J Neurosurg* 1984; 60: 1033-1044.
 31. Boecker H, Wills AJ, Ceballos-Baumann A, et al. Stereotactic thalamotomy in tremor-dominant Parkinson's disease: An H₂¹⁵O PET motor activation study. *Ann Neurol* 1997; 41: 108-111.
 32. Jankovic J, Cardoso F, Grossman RG & Hamilton WJ. Outcome after stereotactic thalamotomy for Parkinsonian, essential and other types of tremor. *Neurosurg* 1995; 37: 680-687.
 33. Koller W, Pahwa R, Busenbark K, et al. High-frequency unilateral thalamic stimulation in the treatment of essential tremor. *Ann Neurol* 1997; 42: 292-299.
 34. Laitinen LV, Bergenheim AT & Hariz MI. Leksell's posteroventral pallidotomy in the treatment of Parkinson's disease. *J Neurosurg* 1992; 76: 53-61.
 35. Sterio D, Beric A, Dogali M, et al. Neurophysiological properties of pallidal neurons in Parkinson's disease. *Ann Neurol* 1994; 35: 586-591.
 36. Baron MS, Vitek JL, Bakay RAE, et al. Treatment of advanced Parkinson's disease by posterior GPI pallidotomy: 1-year results of a pilot study. *Ann Neurol* 1996; 40: 355-366.
 37. Dogali M, Fazzanini E, Kolodny E, et al. Stereotactic ventral pallidotomy for Parkinson's disease. *Neurology* 1995; 45: 753-761.
 38. Iacono RP, Shima F, Lonser RR, et al. The results, implications and physiology of posteroventral pallidotomy for patients with Parkinson's disease. *Neurosurg* 1995; 36: 1118-1125.
 39. Kishore A, Turnbull M, Snow BJ, et al. Efficacy, stability and predictors of outcome of pallidotomy for Parkinson's disease. Six-month follow-up with additional 1-year observations. *Brain* 1997; 120: 729-737.
 40. Kopyov O, Jacques D, Duma C, et al. Microelectrode-guided posteroventral medial radiofrequency pallidotomy for Parkinson's disease. *J Neurosurg* 1997; 87: 52-59.
 41. Krauss JK, Desaloms M, Lai EC, et al. Microelectrode-guided posteroventral pallidotomy for treatment of Parkinson's disease: postoperative magnetic resonance imaging analysis. *J Neurosurg* 1997; 87: 358-367.
 42. Lang, AE, Lozano AM, Montgomery E, et al. Posteroventral pallidotomy in advanced Parkinson's disease. *N Eng J Med* 1997; 337: 1036-1042.
 43. Lozano AM, Lang AE, Galvez-Jimenez N, et al. Effect of GPI pallidotomy on motor function in Parkinson's disease. *Lancet* 1995; 346: 1383-1387.
 44. Soukup VM, Ingram F, Schiess MC, et al. Cognitive sequelae of unilateral posteroventral pallidotomy. *Arch Neurol* 1997; 54: 947-950.
 45. Sutton JP, Couldwell W, Lew MF, et al. Ventroposterior medial pallidotomy in patients with advanced Parkinson's disease. *Neurosurg* 1995; 36: 1112-1116.
 46. Fazzini E, Dogali M, Sterio D, et al. Stereotactic pallidotomy for Parkinson's disease: A long-term follow-up of unilateral pallidotomy. *Neurology* 1997; 48: 1273-1277.
 47. Benabid AL, Pollak P, Gervason C, et al. Long-term suppression of tremor by chronic stimulation of the ventral intermediate thalamic nucleus. *Lancet* 1991; 337: 403-406.
 48. Hubble JP, Busenbark, KL, Wilkinson S, et al. Effects of deep brain stimulation based on tremor type and diagnosis. *Mov Disord* 1997; 12: 337-341.
 49. Dedefvire L, Blatt J-L, Blond S, et al. Effect of thalamic stimulation on gait in Parkinson's disease. *Arch Neurol* 1996; 53: 898-903.
 50. Pfann KD, Penn RD, Shannon KM, et al. Effect of stimulation in the ventral intermediate nucleus of the thalamus on limb control in Parkinson's disease: A case study. *Mov Disord* 1996; 11: 311-316.
 51. Benabid AL, Pollak P, Gao D, et al. Chronic electrical stimulation of the ventral intermediate nucleus of the thalamus as a treatment of movement disorders. *J Neurosurg* 1996; 84: 203-214.
 52. Gross C, Rougier A, Guehl D, et al. High-frequency stimulation of the globus pallidus internalis in Parkinson's disease: a study of seven cases. *J Neurosurg* 1997; 87: 491-498.
 53. Hariz MI & DeSalles AA. The side-effects and complications of posteroventral pallidotomy. *Acta Neurochir Suppl Wien* 1997; 68: 42-48.
 54. Davis KD, Taub E, Houle S, et al. Globus pallidus stimulation activates the cortical motor system during alleviation of Parkinsonian symptoms. *Nature Med* 1997; 3: 671-674.
 55. Limousin P, Greene J, Pollak P, et al. Changes in cerebral activity pattern due to subthalamic nucleus or internal pallidum stimulation in Parkinson's disease. *Ann Neurol* 1997; 42: 283-291.
 56. Pahwa R, Wilkinson S, Smith D, et al. High-frequency stimulation of the globus pallidus for the treatment of Parkinson's disease. *Neurology* 1997; 49: 249-253.
 57. Siegfried J & Lippitz B. Bilateral chronic electrostimulation of venteroposterolateral pallidum: A new therapeutic approach for alleviating all Parkinsonian symptoms. *Neurosurg* 1994; 35: 1126-1130.
 58. Boraud T, Bezard E, Bioulac B & Gross C. High frequency stimulation of the internal globus pallidus (GPI) simultaneously improves parkinsonian symptoms and reduces the firing frequency of GPI neurons in the MPTP-treated monkey. *Neurosci Lett* 1996; 215: 17-20.
 59. Spears J & Mehta V. Neural transplantation in Parkinson's disease: an update. *Dal Med J* 1997; 24: 13-14.
 60. Madrazo I, Drucker-Colin R, Diaz V, et al. Open microsurgical autograft of adrenal medulla to the right caudate nucleus in two patients with intractable Parkinson's disease. *N Eng J Med* 1987; 316: 831-834.
 61. Madrazo I, León V, Torres C, et al. Transplantation of fetal substantia nigra and adrenal medulla to the caudate nucleus in two patients with Parkinson's disease. *N Eng J Med* 1988; 318: 51.
 62. Allen GS, Burns S, Tulipan NB & Parker RA. Adrenal medullary transplantation to the caudate nucleus in Parkinson's disease. Initial clinical results in 18 patients. *Arch Neurol* 1989; 46: 487-491.
 63. Goetz CG, Stebbins III GT, Klawans HL, et al. United Parkinson Foundation Neurotransplantation Registry on adrenal medullary transplants: Presurgical, and 1- and 2-year follow-up. *Neurology* 1991; 41: 1719-1722.
 64. Lindvall O, Backlund E-O, Farde L, et al. Transplantation in Parkinson's disease: Two cases of adrenal medullary grafts to the putamen. *Ann Neurol* 1987; 22: 457-468.
 65. Brown VJ & Dunnett SB. Comparison of adrenal and foetal nigral grafts on drug induced rotation in rats with 6-OHDA lesions. *Exp Brain Res* 1989; 78: 214-218.
 66. Waters C, Itabashi HH, Apuzzo MLJ & Weiner LP. Adrenal to caudate transplantation - A postmortem study. *Mov Disord* 1990; 5: 248-250.
 67. Freeman TB, Olanow CW, Hauser RA, et al. Bilateral fetal nigral transplantation into the postcommissural putamen in Parkinson's disease. *Ann Neurol* 1995; 38: 379-388.
 68. Kopyov OV, Jacques D'S, Lieberman A, et al. Outcome following intrastriatal fetal mesencephalic grafts for Parkinson's patients is directly related to volume of grafted tissue. *Exp Neurol* 1997; 146: 536-545.
 69. López-Lozano JJ, Bravo G, Brera B, et al. Long-term improvement in patients with severe Parkinson's disease after implantation of fetal ventral mesencephalic tissue in a cavity of the caudate nucleus: 5-year follow up in 10 patients. *J Neurosurg* 1997;

- 86: 931-942.
70. Peschanski M, Defer G, N'Guyen JP, et al. Bilateral motor improvement and alteration of L-dopa effect in two patients with Parkinson's disease following intrastriatal transplantation of foetal ventral mesencephalon. *Brain* 1994; 117: 487-499.
 71. Kordower JH, Freeman TB, Snow BJ, et al. Neuropathological evidence of graft survival and striatal reinnervation after the transplantation of fetal ventral mesencephalic tissue in a patient with Parkinson's disease. *N Eng J Med* 1995; 332: 1118-1124.
 72. Kordower JH, Goetz CG, Freeman TB & Olanow CW. Dopaminergic transplants with Parkinson's disease: Neuroanatomical correlates of clinical recovery. *Exp Neurol* 1997; 144: 41-46.
 73. Kordower JH, Rosenstein JM, Collier TJ, et al. Functional fetal nigral grafts in a patient with Parkinson's disease: Chemoanatomic, ultrastructural, and metabolic studies. *J Comp Neurol* 1996; 270: 203-230.
 74. Henderson BTH, Clough CG, Hughes RC, et al. Implantation of human fetal ventral mesencephalon to the right caudate nucleus in advanced Parkinson's disease. *Arch Neurol* 1991; 48: 822-827.
 75. Lindvall O, Brundin P, Widner H, et al. Grafts of fetal dopamine neurons survive and improve motor function in Parkinson's disease. *Science* 1990; 247: 574-577.
 76. Lindvall O, Rehnström S, Brundin P, et al. Human fetal dopamine neurons grafted into the striatum in two patients with severe Parkinson's disease. A detailed account of methodology and a 6-month follow-up. *Arch Neurol* 1989; 46: 615-631.
 77. Lindvall O, Rehnström S, Gustavii B, et al. Fetal dopamine-rich mesencephalic grafts in Parkinson's disease. *Lancet* 1988; 2: 1483.
 78. Freed CR, Breeze RE, Rosenberg NL, et al. Transplantation of human fetal dopamine cells for Parkinson's disease. Results at 1 year. *Arch Neurol* 1990; 47: 505-512.
 79. Freed CR, Breeze RE, Rosenberg NL, et al. Survival of implanted dopamine cells and neurologic improvement 12 to 46 months after transplantation for Parkinson's disease. *N Eng J Med* 1992; 327: 1549-1555.
 80. Lindvall O, Widner H, Rehnström S, et al. Transplantation of fetal dopamine neurons in Parkinson's disease: one-year clinical and neurophysiological observations in two patients with putaminal implants. *Ann Neurol* 1992; 31: 155-165.
 81. Spencer DD, Robbins RJ, Naftolin F, et al. Unilateral transplantation of human fetal mesencephalic tissue into the caudate nucleus of patients with Parkinson's disease. *N Eng J Med* 1992; 327: 1541-1548.
 82. Madrazo I, Franco-Bourland R, Ostrosky-Solis F, et al. Fetal homotransplants (Ventral mesencephalon and adrenal tissue) to the striatum of Parkinsonian subjects. *Arch Neurol* 1990; 47: 1281-1285.
 83. Defer G-L, Geny C, Ricolfi F, et al. Long-term outcome of unilaterally transplanted Parkinsonian patients. I. Clinical approach. *Brain* 1996; 119: 41-50.
 84. Lindvall O, Sawle G, Widner H, et al. Evidence for long-term survival and function of dopaminergic grafts in progressive Parkinson's disease. *Ann Neurol* 1994; 35: 172-180.
 85. Deacon T, Schumacher J, Dinsmore J, et al. Histological evidence of fetal pig neural cell survival after transplantation into a patient with Parkinson's disease. *Nature Med* 1997; 3: 350-353.
 86. Benazzouz A, Boraud T, Féger J, et al. Alleviation of experimental hemiparkinsonism by high-frequency stimulation of the subthalamic nucleus in primates: A comparison with L-dopa therapy. *Mov Disord* 1996; 11: 627-632.
 87. Bergmann H, Wichmann T & DeLong MR. Reversal of experimental parkinsonism by lesion of the subthalamic nucleus. *Science* 1990; 249: 1436-1438.
 88. Guridi J, Herrero T, Luquin MR, et al. Subthalamotomy in parkinsonian monkeys. Behavioural and biochemical analysis. *Brain* 1996; 119: 1717-1727.
 89. Limousin P, Benazzouz A, Hoffmann D, et al. Bilateral subthalamic nucleus stimulation for severe Parkinson's disease. *Mov Disord* 1995; 10: 672-674.
 90. Limousin P, Pollak P, Hoffmann D, et al. Abnormal involuntary movements induced by subthalamic nucleus stimulation in Parkinsonian patients. *Mov Disord* 1996; 11: 231-235.
 91. Goetz CG. New strategies with dopaminergic drugs: modified formulations of levodopa and novel agonists. *Exp Neurol* 1997; 144: 17-20.
 92. Gerlach M, Youdim MBH & Riederer P. Is selegiline neuroprotective in Parkinson's disease? *J Neural Transm* 1994; 41(suppl): 177-188.
 93. Montastruc JL, Rascol O & Senard JM. Glutamate antagonists and Parkinson's disease: a review of clinical data. *Neurosci Biobehav Rev* 1997; 21: 477-480.
 94. Mendez I, Sadi D & Hong M. Reconstruction of the nigrostriatal pathway by simultaneous intrastriatal and intranigral dopaminergic transplants. *J Neurosci* 1996; 16: 7216-7227.
 95. Apostolides C, Sandford E, Hong M & Mendez I. Glial cell line-derived neurotrophic factor improves intrastriatal graft survival of stored dopaminergic cells. *Neurosci* 1998; 83: 363-372.
 96. Rosenblad C, Martinez-Serrano A & Björklund A. Glial cell line-derived neurotrophic factor increases survival, growth and function of intrastriatal fetal nigral dopaminergic grafts. *Neurosci* 1996; 75: 979-985.
 97. Gage FH, Ray J & Fisher LJ. Isolation, characterization, and use of stem cells from the CNS. *Annu Rev Neurosci* 1995; 18: 159-182.

AUTHOR BIOGRAPHY

K. Adam Baker is currently completing his MSc degree in Anatomy/Neuroscience in the Neural Transplantation Laboratory under the supervision of Dr. Ivar Mendez, where he is investigating the optimal site for grafting FVM cells in the rat model of Parkinson's Disease. Previously, he completed his Bachelor of Science with Honours in Neuroscience at Brock University in St Catharines, Ontario.